

International Collating Centre: Summary Report

(1 July to 30 September 2023)

The International Collating Centre (ICC), is overseen by Equine Infectious Disease Surveillance (EIDS) and is generously supported by contributions from Fédération Equestre Internationale (FEI), International Thoroughbred Breeders' Federation (ITBF) members, Japanese Racing Association and Lanwades Stud.



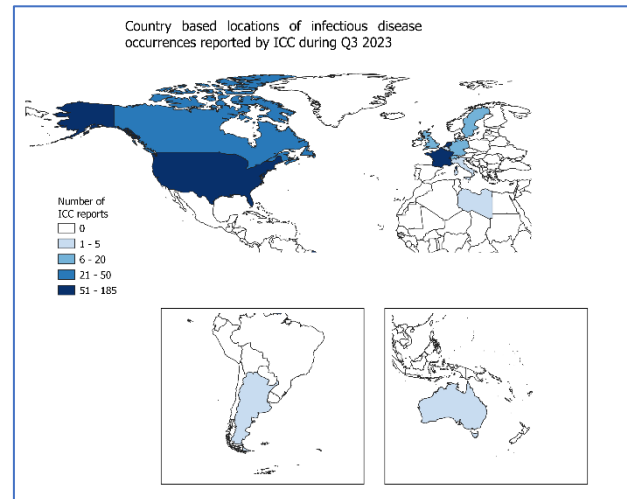
**International
Collating Centre**

National and international equine disease outbreaks are reported on a daily basis by the ICC, through email alerts. Please contact equinesurveillance@gmail.com to receive these. There is also a website available that provides an interactive interface of these infectious disease reports and can be used to view current outbreak reports, <https://equinesurveillance.org/iccview/>.

This article provides a summary of international disease outbreaks during the third quarter of 2023. It should also be noted that additional summary reports were kindly received that included further information on disease occurrence for that country, but which had not been reported in previous real-time ICC reports. This additional information is identified by *or # in the tables and text, where relevant, throughout this report.

The data presented in this report *must be interpreted with caution*, as there is likely to be some bias in the way that samples are submitted for laboratory testing and subsequently reported. Consequently, these data do not necessarily reflect true infectious disease frequency within the international equine population. A country with no reported outbreaks of a disease does not necessarily equate to the disease not being present in that country. Each table below summarises the number of disease outbreaks reported by a country. Each reported outbreak may involve more than one animal.

During Q3 2023, the ICC shared 371 outbreak reports obtained from 14 countries (shaded on the map). Of specific diseases/infections reported, West Nile Virus (WNV) (n=117), strangles (n=102), Eastern Equine Encephalitis (EEE) (n=39) and Equine Herpes virus-4 (EHV-4) (n=25).




Reproductive Diseases

Country	EHV-1	EHV-4
Argentina	#3	-
France	-	1
Germany	1	-
South Africa	#3	-

#some cases reported by ICC after the quarter end

Equine Herpes Virus-1 (EHV-1) Abortion **Argentina**

 #Three outbreaks of EHV-1 abortion were reported after the quarter end. One outbreak involved multiple vaccinated cases and included a case of neurological disease in a pregnant mare and a neonatal foal death. One outbreak with five cases on a premises with 100 recipient mares from different embryo transfer centers and one further outbreak with two cases. Positive diagnoses were confirmed by agent isolation and PCR.

Germany



One case of EHV-1 abortion in a ten-year-old vaccinated Thoroughbred mare on a premises in Lower Saxony. The quarantined mare aborted in her 6th month of gestation. Positive diagnosis was confirmed by PCR on fetal tissue and through a pathological examination.

South Africa



#Three cases of EHV-1 abortion were reported after the quarter end on premises in the Western Cape Province.

Equine Herpes Virus-4 (EHV-4) Abortion

France



One case of EHV-4 abortion was reported in a 15-year-old Carmargue mare on a premises in Gard. Positive diagnosis was confirmed by ELISA on blood.

Respiratory Conditions

Country	EHV-1	EHV-4	Influenza	<i>R. equi</i>	Strangles
Belgium	-	1	-	-	-
Canada	1	-	-	1	3
France	-	7	2	6	19
Germany	-	-	-	-	1
Libya	-	-	1	-	-
Netherlands	2	13	1	7	44
South Africa	#2	-	-	-	-
Sweden	-	-	1	-	5
Switzerland	-	-	-	-	5
UK	-	4	#8	-	-
USA	-	#2	2	-	41

#some cases reported to ICC after the quarter end

Equine Herpes Virus-1 (EHV-1) Respiratory Infection

Canada



One case of EHV-1 respiratory infection was reported in a vaccinated 28-year-old Quarter Horse mare on a premises in Quebec. Clinical signs included: pyrexia, drowsiness, decreased appetite, swollen legs, mild cough and nasal discharge.

Netherlands



Two outbreaks of EHV-1 respiratory infection were reported with single cases in each on separate premises in Limburg. Positive diagnoses were confirmed by PCR.

South Africa



#Two outbreaks of EHV-1 respiratory infection were reported with singles cases in each on premises in Limpopo and Kwa-Zulu Natal, reported after the quarter end.

Equine Herpes Virus (EHV-4) Respiratory Infection

Belgium



One case of EHV-4 respiratory infection was reported in a 14-year-old vaccinated animal on a premises in the Province of Namur, Belgium. Clinical signs included: pyrexia, nasal discharge and cough. Positive diagnosis was confirmed by PCR on a nasal swab.

France



Seven outbreaks of EHV-4 respiratory infection were reported. Six of the outbreaks involved single cases on premises in; Calvados, Eure-et-Loire, Haute-Garonne, Ille-et-Vilaine, Jura, Maine-et-Loire and Orne. One outbreak consisted of two cases on a premises in Calvados. Clinical signs included: cough, lethargy, nasal discharge and pyrexia. Positive diagnoses were confirmed by PCR on nasopharyngeal swabs.

Netherlands



Thirteen outbreaks of EHV-4 respiratory infection were reported with single cases in the majority on premises as follows; Flevoland, Friesland, Gelderland, North Brabant, North Holland, Overijssel, Utrecht. Positive diagnoses were confirmed by PCR.

UK



Four outbreaks of EHV-4 respiratory infection were reported with single cases in each on premises in; Cumbria, County Durham, Lancashire and Wrexham. Clinical signs included: cough, inappetence, lethargy, lymphadenopathy, nasal discharge and pyrexia. One animal had recently aborted at 70 days gestation and one animal had a co-infection of *Streptococcus zooepidemicus*. Positive diagnoses were confirmed by PCR on nasopharyngeal swabs or nasal swabs.

USA



One outbreak of EHV-4 respiratory infection was reported in a two-year-old Thoroughbred colt on a racehorse training facility in Maryland, Baltimore. Clinical signs included: nasal discharge, depression, lethargy and reluctance to move. There was a further 20 animals on the premises of which 18 presented with pyrexia and serous nasal discharge. #An outbreak of EHV-4 respiratory infection was reported in 12 breeding stock animals on one to two sub-units on premises in Kentucky, after the quarter end. Positive diagnoses were confirmed by PCR.

Equine Influenza (EI)

France



Two outbreaks of EI were reported. One outbreak involved a single case on a premises in Correze and one outbreak involved five animals on a premises in Gironde. Positive diagnoses were confirmed by PCR on nasopharyngeal swabs.

Libya



One outbreak of EI was reported in 15 animals on a premises in the Gharyan region, Libya. The animals presented with respiratory disease ranging from mild to severe. Positive diagnoses were confirmed by PCR.

Netherlands



One outbreak of EI was reported involving two animals on premises in Overijssel. Positive diagnoses were confirmed by PCR.

Sweden



One outbreak of EI was reported on a premises in Sunne Municipality, Varmland County.

UK



Eight outbreaks of EI were reported. Seven with single cases on premises in; Buckinghamshire, Devon, Essex, Kent, Norfolk, West Lothian and Worcestershire. One outbreak had two cases in a horse and a donkey on a premises in Flintshire. Clinical signs included: cough, lethargy, lymphadenopathy, nasal discharge, pyrexia and ocular discharge. In two outbreaks animals had recently arrived from Ireland and in a further two outbreaks the affected animals had recently moved onto the premises. Positive diagnoses were confirmed by PCR on nasopharyngeal swabs. #One case of EI was reported after the quarter end in an unvaccinated four-year-old Irish filly on a premises in

Staffordshire. Clinical signs included: lethargy, ocular discharge and initially serous and then mucoid nasal discharge. Positive diagnosis was confirmed by PCR on a nasopharyngeal swab.

USA



Two outbreaks of EI were reported with single cases in each on premises in Pennsylvania and Washington. Clinical signs included: pyrexia, cough, nasal discharge and poor appetite. Two in-contact animals on the Washington premises also presented with pyrexia.

Rhodococcus equi

Canada



One case of *Rhodococcus equi* was reported on a premises in MRC Roussillon, Quebec.

France



Six outbreaks of *Rhodococcus equi* were reported. Five with single cases on premises in; Calvados, Ille-et-Villaine, Loire-Atlantique Orne, Vosges and Yvelines. One further outbreak was reported on a premises Orne. Clinical signs included dyspnoea. Positive diagnoses were confirmed by PCR on nasopharyngeal swabs or by tracheal lavage.

Netherlands



Seven outbreaks of *Rhodococcus equi* were reported. Three with single cases on premises in; Friesland and Gelderland. Four outbreaks with more than one case were reported on premises in; Friesland and Overijssel. Positive diagnoses were confirmed by PCR.

Strangles

Canada



Three outbreaks of strangles were reported. One outbreak had a single case on a premises in Ontario. One outbreak consisted of two cases on a premises in British Columbia and one outbreak involved six cases on a premises in Ontario. Clinical signs included submandibular lymph node abscessation.

France



Nineteen outbreaks of strangles were reported. Sixteen outbreaks involved single cases on separate premises in; Ardeche, Calvados, Deux-Sevres, Doubs, Drome, Eure, Hautes-Alpes, Jura, Manche, Morbihan, Rhone and Yvelines, with one case having a co-infection of EHV-2 and EHV-5. Two outbreaks consisted of three cases on premises in; Haute-Saone and Rhone and one further outbreak was reported in Rhone. Clinical signs included: abscessation, cough, lymphadenopathy, nasal discharge and pyrexia. Positive diagnoses were confirmed by PCR on nasopharyngeal swabs, guttural pouch washes or swabs of purulent discharge.

Germany



One case of strangles was reported on the Swiss-German border. Clinical signs included pyrexia and respiratory tract signs. Positive diagnosis was confirmed by PCR.

Netherlands



Forty-four outbreaks of strangles were reported on premises in; Flevoland, Friesland, Gelderland, Limburg, North Brabant, Overijssel, South Holland Utrecht as Zwolle. Positive diagnoses were confirmed by PCR.

Sweden



Five outbreaks of strangles were reported on premises in; Dalarna County, Orebro Municipality, Sodermanland County, Varmland County and Vasterbotten County.

Switzerland



Five outbreaks of strangles involving single cases were reported on premises in the cantons of Basel-Landschaft, Bern, Glarus, Schaffhausen and Zurich. Clinical signs included: limb oedema, lymph node

abscessation, respiratory tract signs and pyrexia, Positive diagnoses were confirmed by PCR on guttural pouch lavage, lymph node aspirate or nasopharyngeal wash sample.

USA



Forty-one outbreaks of strangles were reported, 35 of which involved single cases on premises in; Florida, Kansas, Indiana, Maryland, Michigan, Ohio, Rhode Island, Washington and Wisconsin. Three outbreaks involved two cases on premises in; Michigan, Washington and Wisconsin. Two outbreaks involved three cases on a premises in; Michigan and Washington. One outbreak involved four cases on a premises in Michigan. Clinical signs included: abscessation, nasal discharge, pitting oedema in all four legs, pyrexia, swollen lymph nodes, sheath oedema, unsteady gait, ventral oedema and weight loss.


Gastrointestinal Diseases

Country	Equine Coronavirus	<i>R. equi</i>	Rotavirus	Salmonellosis
Argentina	-	-	#1	-
Canada	-	-	-	1
France	-	3	6	-
Netherlands	2	-	-	2

#some cases reported by ICC after the quarter end


Equine Coronavirus

Netherlands

 Two outbreaks of Coronavirus were reported on premises in Utrecht and Overijssel. Positive diagnosis was confirmed by PCR.


Rhodococcus equi

France

 Three outbreaks of *Rhodococcus equi* were reported each involving single cases on premises in; Aveyron, Isere and Orne. Positive diagnoses were confirmed by PCR on rectal swabs or faecal material. Clinical signs included: pyrexia, diarrhoea, anorexia and exhaustion. Positive diagnoses were confirmed by PCR on faecal matter or rectal swab.

Rotavirus

Argentina


 #One outbreak of Rotavirus A foal diarrhoea was reported after the quarter end affecting seven foals. The mares had been vaccinated at 60, 45 and 15 days prior to foaling. Positive diagnoses were confirmed by PCR.

France

 Six outbreaks of rotavirus were reported each involving single cases on premises in; Calvados, Orne, Mayenne and Yonne.

Salmonellosis

Canada

 One case of salmonellosis was reported on a premises in Quebec. Clinical signs included: pyrexia, respiratory difficulties, profuse liquid diarrhoea, severe dehydration, cyanotic mucosa and a severe electrolyte imbalance.

Netherlands

 Two outbreaks of salmonellosis were reported on premises in Utrecht and Overijssel. Positive diagnoses were confirmed by PCR.


Neurological Diseases

Country	EEE	EHV-1	Rabies	WNV
Canada	12	1	-	9
France	-	-	-	#18
Germany	-	-	-	#4
USA	29	1	1	93


#some cases reported by ICC after the quarter end

Eastern Equine Encephalitis (EEE)

Canada


 Twelve outbreaks of EEE, each involving single cases, were reported on separate premises in; Ontario and Quebec. Clinical signs included: asymmetrical hyperaesthesia, ataxia, circling, depression, head-pressing, hind-end paralysis, pyrexia, recumbency, cranial nerve deficits, seizures, stiffness, tachycardia, tachypnoea, and weakness and other neurological signs.

USA


 Twenty-nine outbreaks of EEE, each involving single cases, were reported on separate premises in; Florida, Georgia, Maine, Michigan, New Jersey, New York, North Carolina and Rhode Island. Clinical signs included: agonal breathing, inappetence, incoordination, leaning, muscle fasciculations, pyrexia, recumbency and other neurological signs.

Equine Herpes Virus-1 (EHV-1) Neurological Disease

Canada


 One outbreak of EHV-1 neurological disease was reported in a 23-year-old vaccinated mare on a premises in Ontario. Clinical signs included: recumbency and inability to rise. The animal was euthanased.

USA

 One case of EHV-1 neurological disease was reported on a premises in Nevada with veterinary care sought in Utah.


Rabies

USA


 One case of rabies was reported in an unvaccinated five-year-old Warmblood gelding on a premises in Florida. Clinical signs: included ataxia, urine dribbling, self-mutilation, aggression, pyrexia and seizures. The animal was euthanased.

West Nile Virus (WNV)

Canada

 Nine outbreaks of WNV were reported with single cases in each on premises in; Alberta, Manitoba, Ontario and Quebec. Clinical signs included: ataxia, weakness, dull mentation, head tilt, loss of balance, muscle fasciculations, seizures and other neurological signs.

France

 Fifteen outbreaks of WNV were reported with single cases in each on premises in; Bouches-du-Rhone, Charente-Maritime, Gironde, Haute-Corse. Clinical signs included: ataxia, paralysis, pyrexia and neurological signs. #Three outbreaks of WNV with single cases in each were reported after the quarter end on premises in; Bouches-du-Rhone and Haute-Corse. Clinical signs included: ataxia, paresis and

exhaustion. Positive diagnoses were confirmed by ELISA.

Germany



#Four outbreaks of WNV with single cases in each, were reported after the quarter end on premises in: Brandenburg and Saxony-Anhalt.

United States of America



Multiple outbreaks of WNV were reported with single cases in the majority on premises in; California, Colorado, Idaho, Idaho, Indiana, Iowa, Kansas, Kentucky, Michigan, Minnesota, Mississippi, Missouri, Nebraska, New York, North Dakota, Ohio, Oklahoma, Pennsylvania, South Carolina, Tennessee, Utah, Washington, Wisconsin and Wyoming. Clinical signs included: ataxia, hindlimb weakness, inappetence, lethargy, muscle fasciculations, recumbency, tachycardia and other neurological signs.

Miscellaneous Diseases

Country	AHS	Ana-plasmosis	EIA	EVA	Hendra	Lyme Disease	Piro-plasmosis	Potomac Horse Fever	VS
Australia	-	-	-	-	1	-	-	-	-
Canada	-	-	4	-	-	-	-	1	-
France	-	-	1	-	-	-	-	-	-
Italy	-	-	3	-	-	-	-	-	-
Netherlands	-	1	-	-	-	-	1	-	-
South Africa	#9	-	-	-	-	-	#52	-	-
Switzerland	-	1	-	-	-	-	1	-	-
USA	-	-	10	1	-	1	-	2	7

#some cases reported by ICC after the quarter end

African Horse Sickness (AHS)

South Africa



#AHS is regarded as endemic in South Africa except in the AHS controlled area in the Western Cape Province. Cases were reported in six of the provinces, after the quarter end, as follows: Eastern Cape (one case), Gauteng (three cases), Kwa-Zulu Natal (two cases), Northern Cape (one cape), North West Province (one case) and Limpopo (one case).

Anaplasmosis

Netherlands



One case of anaplasmosis was reported involving a single case on a premises in South Holland. Positive diagnosis was confirmed by PCR.

Switzerland



One case of anaplasmosis was reported on a premises in the Canton of Vaud. Clinical signs included pyrexia. Positive diagnosis was confirmed by PCR.

Equine Infectious Anaemia (EIA)

Canada



Four outbreaks of EIA were reported. Three outbreaks involved single cases on premises in; Alberta and British Columbia. One outbreak involved three cases on a premises in British Columbia.

France



One case of EIA was reported in a donkey on a premises in Hautes-Alpes. Positive diagnosis was confirmed by serology.

Italy



Three outbreaks of EIA were reported with single cases in each on premises in the Region of Lazio.

USA



Ten outbreaks of EIA were reported. Seven outbreaks involved single cases on premises in: Florida, Mississippi, Oklahoma and Texas. There were also seven cases on three separate premises in Texas.

Equine Viral Arteritis (EVA)

USA



One outbreak of EVA was reported in 12 newborn foals on a premises in Pennsylvania. The animals presented with severe interstitial pneumonia and had died.

Hendra

Australia



One case of Hendra was reported in an unvaccinated 24-year-old animal on a premises in New South Wales. Clinical signs included: depression, incoordination, nasal discharge and pyrexia.

Lyme Disease

USA



One case of Lyme disease was reported in an unvaccinated 19-year-old Standardbred gelding on a premises in Ohio. Clinical signs included mild musculoskeletal pain.

Piroplasmiasis

Netherlands



One case of piroplasmiasis was reported on a premises in Utrecht. Positive diagnosis was confirmed by PCR.

South Africa



Piroplasmiasis is regarded as endemic in South Africa with cases reported from eight of the nine provinces, after the quarter end, as follows: a case of *B. Caballi* in Gauteng (one case) and cases of *T. equi* in: Free State (one case), Gauteng (24 cases), Kwa_Zulu Natal (two cases), Mpumalanga (three cases), Northern Cape (three cases), North West Province (two cases), Western Cape (15 cases) and Limpopo (one case).

Switzerland



One case of piroplasmiasis was reported on a premises in the Canton of Valais. Clinical signs included emaciation. Positive diagnosis was confirmed by PCR.

Potomac Horse Fever

Canada



One case of Potomac Horse Fever with a co-infection of *Clostridium difficile* was reported on a premises in Quebec. Positive diagnosis was confirmed by PCR.

USA



Two outbreaks of Potomac Horse Fever were reported on premises in; Ohio and West Virginia. Clinical signs included: diarrhoea, inappetence, lethargy and pyrexia.

Vesicular Stomatitis

USA



Since the start of the VS outbreak on 17 May 2023, 203 VS premises have been identified (70 confirmed positive and 133 suspected) in three states; California, Nevada and Texas. One hundred and ninety-nine of these premises had only equine species clinically affected. Of the 203 total VS affected premises, 201 have completed the quarantine period with no new clinical cases and have been released from quarantine. Two premises in California remain in quarantine.