

# Why racehorses can go weak at the knees

If you were to design a supporting strut, to bear the equivalent of half a ton at speed of around 35mph, and you were limited to a structure less than 30cm in diameter, you probably wouldn't include in it a bag of marble-sized small odd-shaped bones, which fit together like a jigsaw puzzle, but that's exactly what the evolution of the horse has done. The horse has a problem, in that it needs to support its huge body weight at speed on a stiff rigid structure, often using only one leg at a time (see fig 1) and yet also has to fold this structure up in order to bring it forward for the next step. The structure has to be rigid and stable when supporting weight, but equally extremely flexible in order to be moved forward, and it is these conflicting demands that make the knee the shape and size it is.

The equine knee (the carpus) is the equivalent of our wrist. Unlike our wrist, however, it does not flex in every direction but is limited to movements in the sagittal plane only. When one picks up a horse's leg, the normal knee flexes with almost no resistance, so that the cannon bone lies almost parallel to the forearm. When the leg is weight bearing, however, it's essential that both medial and lateral movement of the limb are eliminated and that the limb assumes a completely stable, strut-like position. Bending the knee in the opposite direction, as we would do when raising our hand to wave, is simply not acceptable.

To enable this limited movement and extreme stability under loading, the knee has evolved to a complex interlocking arrangement of small bones. There are six major bones which comprise the load-bearing component of the knee, and in injury terms the most important of these are the radial carpal bone and the third carpal bone (fig 2, arrows).

Approximately two-thirds of the body weight of the horse is taken through the front legs during galloping, and the majority of this is down the medial aspect of the limb. This combination illustrates why the radial carpal bone and the third carpal bone are so important in the athletic horse. When the knee takes full load the small bones interdigitate with each other to fit snugly together and 'close-pack'.

These tiny bones are wrapped in incredibly dense connective tissue, forming



**Figure 1:** A horse galloping at speed, with its entire weight being borne on the right fore leg. Notice how the extreme forces push the knee slightly backwards (white arrow). The leg is prevented from collapsing completely by support from the palmar carpal ligament, a thick 'strap' running from the back of the forearm to the top of the cannon bone

MANDY DAVIS/SPORTING CHANCE RACING

ligaments both between the bones, and between the whole of the knee and the upper and lower portion of the limb. The small inter-carpal ligaments allow the flexion of the knee as the limb is brought forward, but once the knee is in the 'close-packed' weight-bearing position they prevent the bones moving beyond a certain range. In doing so, the stretching of these ligaments absorbs some of the shock otherwise taken by the bones alone.

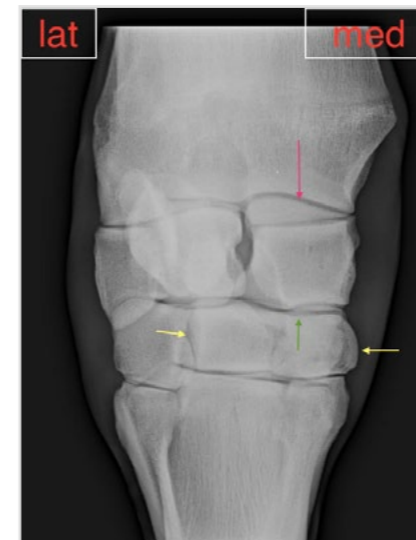While knee trouble is one of the most common problems we see in the racehorse, many go through their careers without having any trouble at all, and what has come under increasing scrutiny is just why the horses which suffer knee problems do so. Are they inherently weak, are we doing something wrong with them, or do they simply have such poor conformation that the strength of the bone is overwhelmed by abnormal loading forces? The answer to these questions is probably a bit of all three, as we will now go on to consider under the individual problems.

## Carpitis

This term is used as a bit of a 'bucket' group to contain any horse which is

showing lameness in association with inflammatory changes in the knee such as heat, pain or swelling but shows nothing on radiography. Carpitis simply means inflammation of the knee and doesn't really tell us anything about the causation, it is more a description of the symptoms. The causation can be that we have trained the horse too rapidly for it to have had time to adapt the ligaments which hold the knee bones together. These have therefore stretched beyond their normal range, causing inflammatory changes. We may simply have gone too fast too soon, without allowing the animal adequate time to accommodate to the increasing loads upon its knees. Similarly, cartilage may be inadequately developed in some horses and this will wear, producing signs of inflammation within the knee.

These early changes if not taken seriously can lead to lifelong degenerative joint disease (arthritis), and we therefore have to pay attention when the horse is telling us that the knee is having trouble. In horses with very poor carpal conformation (fig 3) even normal training loads and a very slow progression in training speeds can produce carpitis simply because the conformation



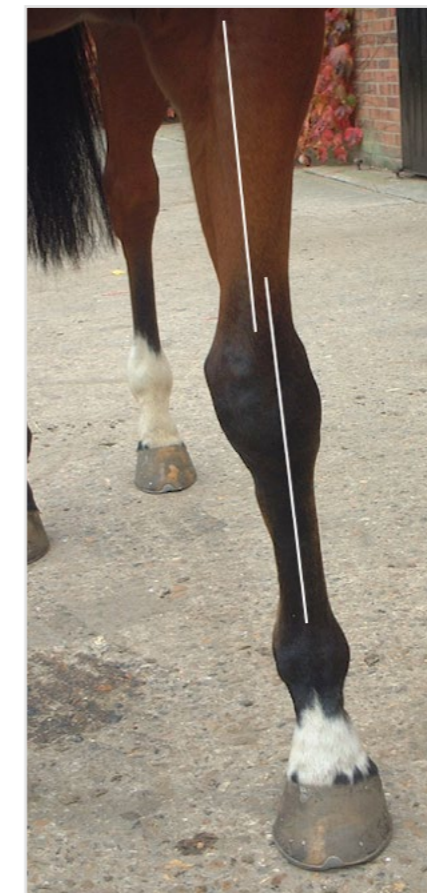**Figure 2:** Dorsopalmar view of the right knee of a racehorse. The most important weight-bearing structures, and therefore the seat of most of our problems, are the radial carpal bone (red arrow) and the third carpal bone (yellow arrow). Because most of the weight is borne down through the medial aspect of the limb, the 'cup' in which the radial carpal bone sits (the radial facet) bears enormous loads (green arrow)

exaggerates the loading some parts of the knee have to undergo. These horses present more of a problem because once they have been rested and rehabilitated, the knee conformation will still be the same and will probably lead to overload a second time around. These can be some of the more difficult horses to keep sound, and many trainers will have a favourite 'bête noire' knee conformation which they will remember having struggled with in the past, and will avoid like the plague when looking at yearlings in the future.

## Chip fragmentation

While in theory chip fragments can occur off any of the knee bones, by far the most common is the distal edge of the radial carpal bone (fig 4). This is the force concentration site when the knee is close packed and the weight is being borne down through the medial aspect of the limb. We used to think that these chip fractures occurred as a simple result of one-off physical overload of the bone as a structural entity. We now know that, as with almost all other racehorse injuries, these injuries are often 'fatigue' fractures.

This doesn't imply that the horse is fatigued, rather that the material properties of the structure (in this case bone) have become fatigued after repeated sub-maximal loading. Metal fatigue in aircraft

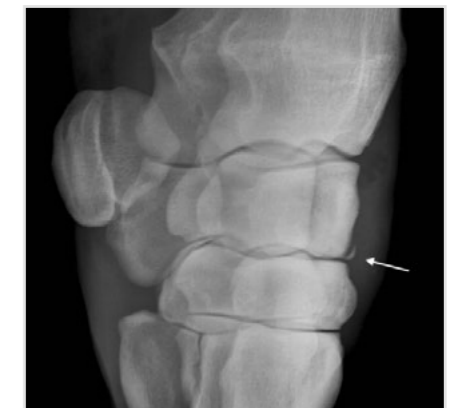

**Figure 3:** An example of poor knee conformation, enough to challenge the ligaments and bones comprising the knee. Here the knee is 'offset', in that the middle of the cannon bone is situated to the side of the middle of the forearm (white lines). This places exaggerated loading on some of the small bones within the carpus

parts is a very similar phenomena.

Some years ago a very experienced track clinician and surgeon working on the Californian race tracks, Greg Ferraro, collected all of the chip fractures he removed from racehorses and sent them to one of his colleagues, Roy Poole, a pathologist then working at the University of California in Davis. Ferraro wanted to know just how many of these chip fractures were normal bone that had just cleaved away, and how many were actually pathological fractures of already diseased bone. The surprising answer came back that 100% of the fragments showed pre-fracture fatigue changes. In other words, these chip fractures give us plenty of notice that they are about to occur, if only we could pick up the signs.

Treatment is usually by surgical removal of the fragment itself and smoothing off of the fracture fragment 'bed'. Once this has been carried out the joint cartilage will



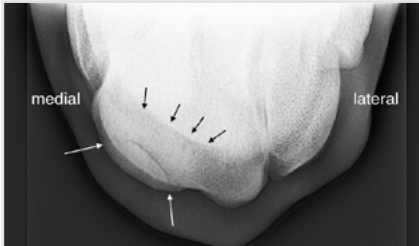
**Figure 4:** An example of a displaced small chip fracture of the distal radial carpal bone. This is the commonest site for chip fragmentation in the knee as a result of the force-concentration peaking in this site

never be the same again, but the fracture 'bed' will be covered with a relatively weak form of fibro-cartilage, and this will at least form a seal. Chip fractures are not always removed, and some horses will tolerate the presence of a small chip reasonably well. However, we know that the presence of osteochondral fragments within a joint will almost invariably lead to the development of arthritis, and therefore be limiting to the long-term future of that horse. In conjunction with this, arthroscopic removal using tiny skin portals, in combination with microsurgical instruments, has made the removal of chip fractures a much less risky and traumatic procedure than it used to be.

## Third carpal bone densification and fractures

The third carpal bone sits between the radial and intermediate carpal bone and the top of the cannon bone. Unlike the row of bones at the top of the knee, which have dense elastic ligaments between them allowing them to 'flex' on weight bearing, the third carpal bone is fixed as the 'meat in the sandwich', and cannot move. For this reason in horses that are trained too rapidly or in horses where the conformation of the limb produces abnormal forces in the knee, damage to the third carpal bone, particularly in the 'cup' which holds the radial carpal bone (fig 2), is relatively common. This damage manifests itself in a way which we can often see on radiographs. When the spongy flexible bone within the third carpal bone is damaged, the body goes in to repair it, often by laying down more bone mass.

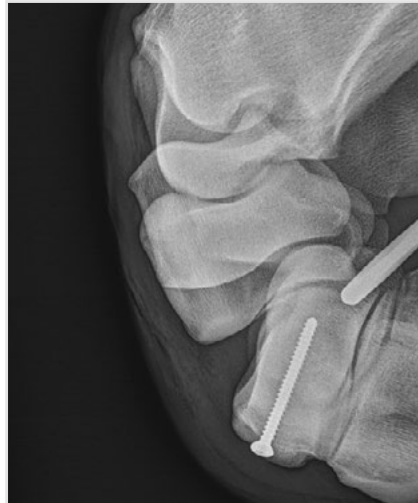This bone mass is visible as whiteness on a radiograph known by radiologists as >>>



**Figure 5a:** A flexed view looking down on the left knee of a racehorse. Note the area of third carpal bone that has become increased in density (sclerotic, black arrows) causing it to become 'stiff'. This bone has eventually fractured through the centre of this area of sclerosis (white arrows)

» sclerosis. Although the aim of the repair of the damaged bone is to increase its strength, increased bone mass also increases the brittleness of the bone, so that rather than being like a flexible piece of plastic, it becomes like a piece of stone. As the presence of so many ancient buildings shows us, stone is very good at bearing weight but is less good at dealing with sudden or repeated impact. In fact this is just the way that stones are carved to produce the building blocks. When the third carpal bone becomes sclerotic, it withstands repeated cyclical loading over a period of time, but eventually may begin to crack, and these cracks often propagate to become a full fracture of the bone.

These fractures can run in two or three different directions but the most common are the sagittal fracture, where the bone simply splits in two, or the



**Figure 5b:** The same bone seen in figure 5a following surgical fixation of the slab fracture with a carefully placed screw

slab fracture, where a segment, usually immediately through the sclerotic radial fore set, explodes outwards (fig 5).

Our problem with third carpal bone fractures is that we cannot really remove the fractured part of the bone as it is so big and bears such a lot of load. We therefore have two alternatives: one is to rest the horse and try to allow the fracture fragments to heal. Healing is usually relatively poor though, because with every step the horse takes the fracture fragments move - there is simply nothing there to hold them together. The other alternative is to fix the fracture by insertion of a screw. The prognosis following screw fixation has in the past been relatively poor,

because placement of the screw to ensure complete joint congruity was very difficult.

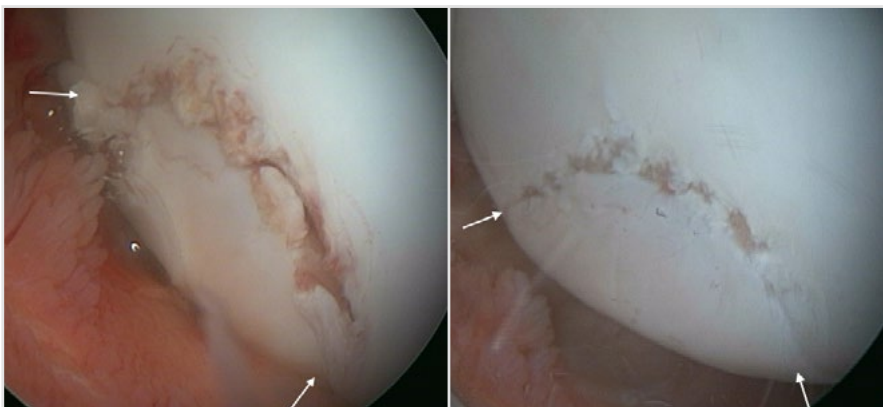
With the advent of arthroscopic 'keyhole' surgery, allowing the surgeon to evaluate the surface of the joint at the same time as inserting the screw, fracture fixation is much more accurate, and the congruity of the joint surface following surgery can be extremely good (fig 6). The advent of intra-operative CT scanning, allowing three-dimensional reconstruction of the bone, has also greatly facilitated accurate screw placement.

Not all horses with sclerosis of the third carpal bone go on to fracture, but many of them show lameness, often only transient, after full-speed exercise or racing for the remainder of their careers. As this condition is reversible in the young horse with rest, but becomes less so with age, early diagnosis is the key.

## Intercarpal ligament injury

As we have said in the preceding part of the article, the bones are by far the most obvious components of the knee, but they would be completely useless as load weight-bearing structures were it not for the dense connective ligaments which hold them together. The biggest of these is the palmar carpal ligament, a thick strap-like 'belt' which runs down the back of the knee from the end of the radius to the top of the cannon bone. In addition there are various small intercarpal ligaments joining the carpal bones together and all of these can undergo tearing. Horses affected by carpal ligament tears will show lameness, swelling of the knee and will 'block out' to installation of local anaesthetic into the knee, but will show nothing on x-ray. This is where Magnetic Resonance Imaging (MRI) has allowed massive steps forward in accurate diagnosis, as these ligaments can now be clearly visualised. Once the diagnosis is made then it may be judicious for the torn part of the ligament to be tidied up or removed, again using keyhole surgery, so that the inflammatory 'drive' within the joint is lessened. As yet, we have no structure strong enough to use as a replacement ligament, something which is done surgically in dogs and cats.

There are many other injuries which crop up sporadically associated with the knee, but the four syndromes described above will encompass around 90% or more of the conditions seen in racehorse practice. Advances in imaging and surgical technique in the last 20 years have greatly improved the management of these conditions, though they still account for a good proportion of the causes of retirement.



**Figure 6a and b:** An arthroscopic intra operative view of the fracture shown in figure 5A prior to the placement of the screw (6a). Note the large irregular fracture gap in the joint surface (between the white arrows).

Following reduction with the screw (6b), the gap is closed and the joint surface now looks far more normal, with only some small fragments of cartilage missing. These too will eventually heal by development of fibro cartilage. This degree of joint congruity could never be achieved with non-surgical management