

Orthopaedic corrective surgeries in foals and yearlings: is there a need?

Corrective orthopaedic surgeries are performed on foals and yearlings as elective procedures to improve their odds of reaching their full athletic potential, increase their sporting longevity and ultimately increase sales value. These surgeries can be broadly categorised into osteochondrosis removal, angular limb deformity correction, flexural limb deformity and management of subchondral bone cystic lesions.

When do we perform these surgeries?

This is variable, and the time window to correct some orthopaedic problems is short, therefore it goes without saying that we need to be aware of the optimal time to operate during their development.

For angular limb deformities it is important to note that growth plates close and after this has occurred, the growth potential and angulation cannot be influenced. When operating to prevent fetlock varus (toeing in), the distal cannon bone closes at approximately six months with decreased growth after three months; this will affect fetlock angulation. However, the distal radius and distal tibia growth plate closes at two years so knee and hock varus angular deformities are operated on as yearlings.

Osteochondrosis fragments can improve/resolve up to 18 months of age, therefore removal of these lesions should be delayed until their yearling year. When a foal becomes contracted (flexural limb deformity), medical management can be initiated but if the foal fails to respond at that point surgery is often indicated to prevent secondary complications.

When evaluating foals and yearlings, another consideration should be whether there are any time constraints in relation to sales and sales prep. This needs to be incorporated into our planning matrix to determine when lesions are best operated on.

Angular limb deformities

The drive to achieve a desired limb conformation is to maximise their athletic ability, limit injury and

manage the stresses of training to increase sales value by creating a protective conformation. An angular limb deformity is diagnosed when the limb deviates from the frontal plane. The most commonly affected joints are fetlocks followed by the knee and hocks. There is a heritability for conformational traits, as well as acquired causes such as phytitis, a heavy weight and nutrition. A varus deviation is seen as the lateral aspect of the limbs grows faster compared to the medial side of the limb.

To diagnose an angular limb deviation, a dynamic evaluation is very important, ensuring the patient is assessed walking on a flat surface away and towards the assessor as well as standing square. If deemed necessary the growth plate can be assessed for closure with radiographs and if the deformity is severe radiographs can highlight congenital abnormalities.

To treat a fetlock varus, the foal is ideally operated on at approximately 8 weeks and no later than 12 weeks. For a carpal deviation, placement of a transphyseal screw between 12-16 months is the aim, however if there is a severe carpal valgus it may be necessary to treat as a foal.

Treatment options include conservative management as well as surgical. The foal should be evaluated at six weeks of age. Farriery includes trimming and placement of lateral extensions to increase the force going through the outside of the foot and decrease growth on that side. Care needs to be taken not to distort the hoof capsule at this age. However, as the foal is closely monitored over the next 2-4 weeks, care does need to be taken with nutrition, so their weight gain is controlled. If improvement is not seen, a quick decision needs to be made about surgery.

Surgical approaches include:

- growth acceleration i.e. periosteal strip
- growth retardation i.e. transphyseal screw, transphyseal bridging with screw and wire or staple
- osteotomy/ostectomy - reserved for adults with severe deformities

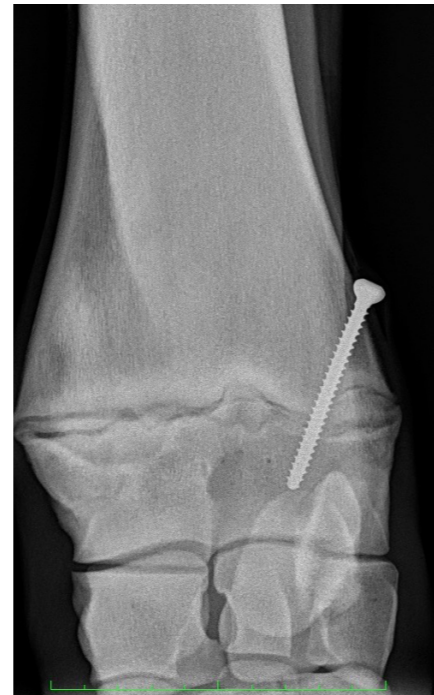

Figure 1 A dorso-palmar radiograph of the knee illustrating a transphyseal screw placed across the lateral aspect of the distal radial growth plate to retard growth, to treat a carpal varus angular limb deformity

Data sets in small groups of foals indicate that periosteal strips have no effect on growth, so this is less commonly performed currently. However, there may be a place for this in foal carpal valgus. The procedure is performed under a quick general anaesthesia, via a small incision on the outside of the limb for a carpal valgus and the periosteum is elevated to speed up growth on this side. Recovery is fast from this procedure.

Transphyseal screws are more commonly performed and favoured out of the corrective surgical options to treat fetlock and carpal varus. Baker et al. showed yearlings treated for carpal varus with this procedure compete as well as their siblings that were not diagnosed with this angular limb deviation. The surgical procedure is performed under a brief anaesthetic with a small incision, on the outside of the limb for a knee or fetlock varus, and a screw is inserted across the growth plate to retard growth on that side.

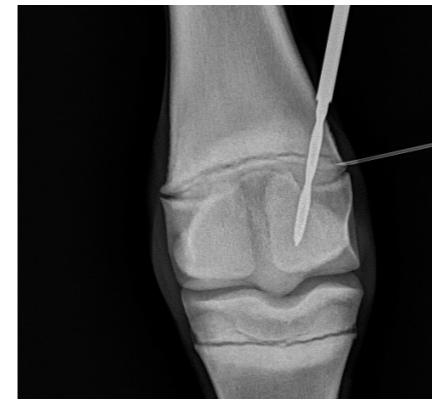

Figure 2 Intra-operative radiograph during placement of a lateral 4.5mm screw for treatment of a fetlock varus angular limb deformity. The drill bit is across the lateral aspect of the distal cannon bone growth plate

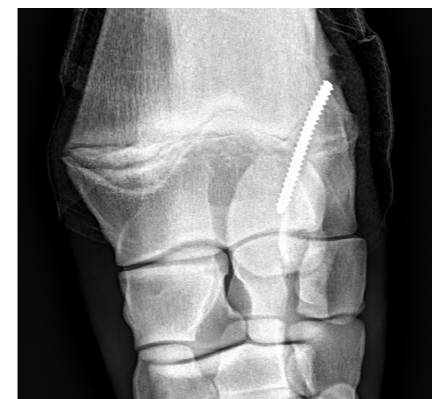

Figure 3 A pre-operative radiograph of a bandaged knee where the transphyseal screw head has broken off during the attempted standing screw removal. This will be removed under general anaesthesia with a broken screw kit

Serial evaluation is essential both pre- and post-operatively to ensure surgery is the correct option and that we reach the correct angulation once the screw is placed; if the screw is left in place longer than is needed, overcorrection can occur. Post-operative bandaging and stall rest for between two and three weeks is desired. The screw is removed typically standing with sedation and local anaesthetic. Screws can snap as the implant is removed; this has no long-term effect but in the short term will require an anaesthetic and special equipment for removal.

Acquired flexural limb deformity

These deformities occur in the sagittal plane where a joint is held in an abnormal flexed or extended position. This is typically seen in growing horses. Common regions where these

flexural deformities occur are the coffin joint region or fetlock region. Less commonly these are seen in the pastern or knee. It is thought to occur in rapidly growing foals where the bone growth is greater than the musculotendinous units, which can be hereditary or related to nutrition. Pain has also been blamed for flexural deformities; when growth rate in the soft tissue and bones are not matched, this is painful, leading to the development of a contracture.

Diagnosis typically occurs between one and six months of age and is made via thorough routine assessments on solid ground where angulation of the foot can be seen. Conservative management consists of correcting the nutritional plane, ensuring appropriate calorie intake and assessing balance of minerals. If still on the mare, weaning early or decreasing the mare's concentrates may be required. Pain relief and exercise to control any painful stimuli can be helpful. Farriery is important, especially in flexural deformities in the coffin joint region where rasping the heels over time can help treat contracture.



Figure 4 A foal presenting for an inferior check ligament desmotomy bilaterally in front for contracture in both coffin joints; worse contracture present in the right front (the farthest away limb)

If surgery is required, what are the options?

For contracture in the coffin joint region: desmotomy of the inferior check ligament, or rarely a tenotomy of the DDFT. The inferior check ligament desmotomy is made through an incision on the side of the limb and the accessory ligament of the DDFT is isolated and transected under a general anaesthesia.

For contracture in the fetlock joint region: desmotomy of the inferior or superior check ligament. The latter is performed typically tenoscopically, the accessory ligament of the SDFT is transected in the carpal sheath

Post-operatively, the convalescent period is short and farriery will need to be

performed at the same time. The outcome is favourable if a mild to moderate contracture is corrected.

Osteochondrosis (OC)

A definition of osteochondritis dissecans (OCD) is the failure of endochondral ossification with the formation of fragmentation. It is thought to be related to impaired or damaged vascular supply to the immature cartilage that is ossifying and occurs at specific predilection sites. These include sites in the hock, stifle and fetlock. OC lesions can form and heal back with no intervention, hence these should ideally not be removed until that time frame to repair has passed which varies between joints. At 12 months of age most lesions are considered to be permanent though some can improve up to 18 months in the stifle and new lesions can form in the fetlock up to 18 months old.

OCD is caused by several factors culminating in loose cartilage and fragmentation of the subchondral bone. These factors consist of nutrition with trace mineral imbalances being important, rapid growth/large size, hormonal imbalances and genetic links. Trauma or exercise can then loosen OCD fragment

Clinical signs can be variable. When the horse isn't working, they are often clinically silent with no overt lameness or joint effusion and are detected on screening radiographs. Once in work they can cause joint effusions and lameness at high speed, hence the need for treatment. Treatment consists typically of arthroscopic fragment removal. This is keyhole surgery, under a general anaesthesia. The yearling would typically be admitted the day prior to surgery and discharged the day after surgery all being well. Rehab is often between 4-8 weeks of restricted exercise.

Is there a need for all fragments to be removed?

It is important to note that opinion is varied as data is lacking in this field, though it is probably reasonable to suggest that the veterinary profession would agree some fragments are more likely to cause an issue than others. The international veterinarians and market are less forgiving, believing more fragments are likely to cause lameness, joint effusions and/or hinder a foal or yearling's athletic career. Sometimes this may actually only be seen in that horse's second career and decrease the risk for osteoarthritis.

» **Exact examples of where there are varying views on degree of impact of osteochondrosis lesions in a horse's career are seen below:**

- This accessory carpal bone fragment is rare and many would not link this to lameness but on the rare occasion you can get joint effusion.

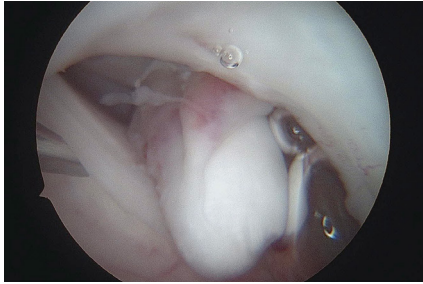


Figure 5 An arthroscopic view of an OC fragment from the dorsal aspect of the accessory carpal bone in the knee

- However, hock DIRT lesions and stifle lateral trochlear ridge OCD lesions are more concerning and often cause effusion even as a yearling.

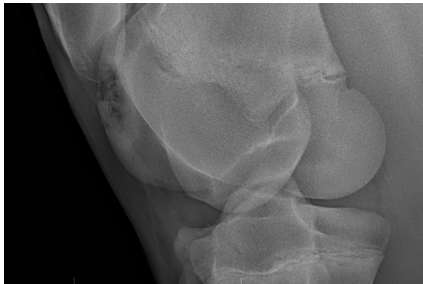

Figure 6 An oblique radiograph of the stifle highlighting the femoral lateral trochlear ridge with a large sized OC lesion present; this is likely to become clinical if not treated arthroscopically and the size could limit athletic potential

- Then proximal P1 fragments in the fetlock are variable; whether they are dorsal or palmar/plantar (front of the joint vs back of the joint) could affect the possibility of lameness and the jury is still out on these.

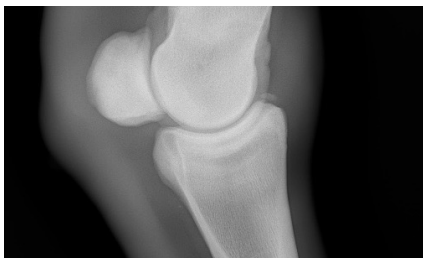

Figure 7 A latero-medial radiograph of a fetlock with a moderate sized osteochondral fragment off the dorsoproximal aspect of P1

Yearlings are screened and decisions are made as to whether to remove the fragments with the stud manager, farm veterinarian and surgeon. Recently a surgery has been developed to pin cartilage flaps back down on the lateral trochlear ridge of the stifle. This surgery works before the cartilage ossifies. This is an arthroscopic procedure where absorbable darts/pins are placed through the cartilage flap securing it to the subchondral bed with the aim of resolving or decreasing the size of the lesion as the weanling grows. This would require earlier radiographic screening to assess whether that weanling would benefit from this surgery.

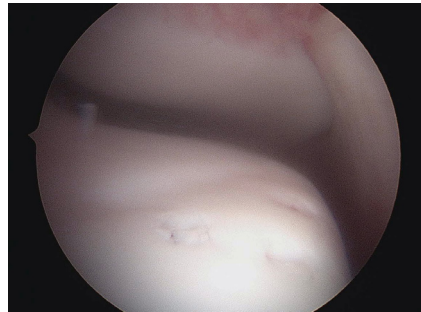


Figure 8 is An intra-operative arthroscopic view placing osteochondral darts to treat an OC lesion on the lateral trochlear ridge of the stifle. The dimples indicate where the darts have been placed

Outcomes are favourable: 75% of hock OCD removals will race with a decreased risk of osteoarthritis. The outcome is good in the fetlock especially if no wear lines and with stifle lesions the outcomes are better the smaller the lesion.

Subchondral bone (SCB) cysts

The pathogenesis of SCB cysts is debated; it is often considered part of the osteochondrosis disease and a failure of the endochondral ossification process, however other research groups put these down to trauma. Common predilection sites are the medial femoral condyle, distal cannon bone and distal P1. Clinical signs are variable, they may be silent and found on screening radiographs or they can be associated with lameness and joint effusion typically at the start of training. Diagnosis is typically made by radiography.

There are many treatment options, and when this is the case it typically indicates nothing has been found to be successful routinely. The size of the lesion, location of the subchondral bone cyst, age as well as the intended use will all play a role in the selected treatment for that specific animal. Overall success is better typically

in animals treated under three years old; however, size, location, pre-existing joint pathology and clinical signs will also play a role in success.

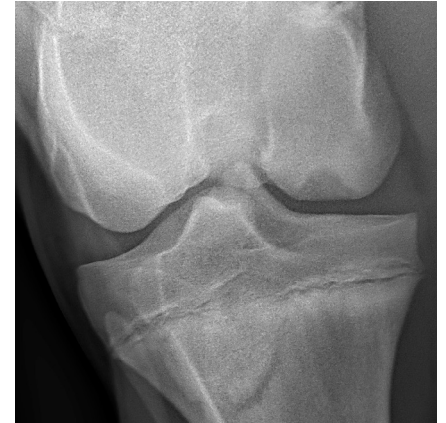

Figure 9 A caudo-cranial stifle radiograph depicting a large medial femoral condyle subchondral bone cyst which was then treated with an interference absorbable screw

As a yearling or two-year-old,, the favoured treatment options are currently a transcondylar screw which alters the biomechanics and loading of the condyle to promote bone formation; or insertion of an interference (absorbable) screw after curettage. The first is performed by radiographic and often arthroscopic guidance; a cortical screw is placed in lag fashion across the cyst. The 7mm inference screw is inserted via a drill tract under radiographic guidance, with curettage and flushing of the cyst prior to insertion. This screw can't be visualised on radiographs, which is seen as one of the main advantages to this technique. Typically, there is a 4-8 week period of rest.

Other treatment options include intra-lesional corticosteroid injection under general anaesthesia, cyst curettage (debridement via arthroscopy or through the bone) and also grafting techniques performed via arthroscopy to fill the cyst and promote bone formation.

Conclusion

In summary the aim of these corrective surgeries is to help that foal or yearling reach its full potential. Improving conformation with transphyseal screws; removing osteochondral fragments via arthroscopy; and trying to help heal subchondral bone cysts with a screw placement are thought to help achieve this aim. These surgeries are minimally invasive with typically short post-operative lay-up periods, and the outcome to race tends to be good.